

ERCP Tissue Sampling - A rare diagnosis made by the Histoguide® wire-guided forceps

Parth J. Parekh, M.D. Mohammad H. Shakhatreh, M.D. MPH,
Douglas Grider, M.D FASDP, Paul Yeaton, M.D., Carilion Clinic.



Procedure:

ERCP (endoscopic retrograde cholangiopancreatography) with indication for biliary sampling.

Indications:

A 72-year-old male was referred for new onset jaundice, pruritus, and decreased appetite. Laboratory evaluation was consistent with cholestatic jaundice (AST/ALT 144/164, alk phos 515, tbili 25). Imaging demonstrated intra-hepatic and proximal common bile dilation with an abrupt transition point causing near complete obliteration of the intrapancreatic portion of the common bile duct.

Method 1:

The patient underwent an ERCP demonstrating a 12mm stricture with proximal dilation. A biliary sphincterotomy was conducted followed by brushing to obtain cytology samples. A fully covered metal stent was placed to allow for decompression.

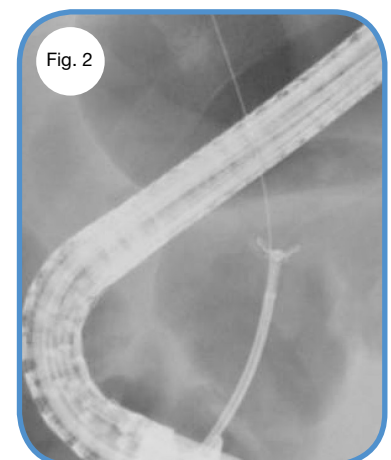
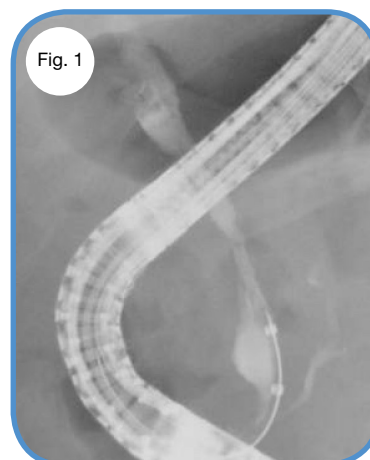
Results from Method 1:

The bile duct cytology was negative for malignancy, demonstrating abundant bile duct epithelium with reactive cellular changes.

Method 2:

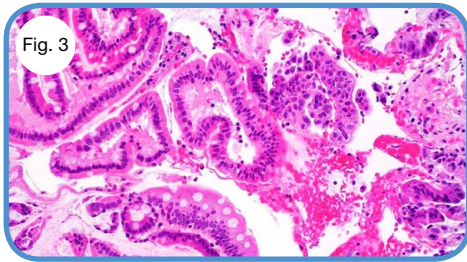
Approximately 2 weeks later, a repeat ERCP was performed which again demonstrated a common bile duct stricture (Fig 1).

The Histoguide® wire-guided forceps was used to obtain multiple biopsies from the stricture (Fig 2).



continue to method 2 results →

Results from Method 2:



Pathology from the the biopsies obtained with the Histoguide[®] wire-guided forceps demonstrated a low-grade biliary intraductal papillary neoplasm (Fig 3). As a result, the patient was scheduled to undergo a Whipple procedure.

Discussion:

“B-IPMN (biliary intraductal mucinous neoplasm) is an uncommon entity characterized by papillary growth within the bile duct lumen. It is thought to in some ways resemble P-IPMNs (pancreatic intraductal papillary mucosal neoplasms); both of which are mucin producing tumors that arise from epithelial cells and demonstrate a papillary growth pattern. There are clinicopathological differences between the two entities, suggesting that they are a result of two distinct underlying biological pathways. These differences may account for the higher propensity of B-IPMNs to undergo malignant transformation compared to P-IPMNs. Thus, early diagnosis is pivotal as surgical resection can be curative. This case describes a new technique which can be used to make such a rare diagnosis.”